Applied Cancer Research 2005; 25(3):108-115

Review Article

Advances in bone and cartilaginous tumours

S. Romeo, A.M. Cleton-Jansen, J.V.M.G. Bovée, P. C.W. Hogendoorn
Department of Pathology, Leiden University Medical Centre, The Netherlands

Key words: Bone neoplasms. Osteosarcoma, cartilaginous tumours, osteochondroma, chondrosarcoma

"Si un hombre nunca se contradice, sera' porque nunca dice nada"[1]

Except for the description of a number of specific clinicopathological entities, the twentieth century was not the scenery of any spectacular progress in the field of bone and cartilaginous tumour pathology. A major breakthrough came out in the seventies, with the advent of chemotherapy for the treatment of osteosarcoma. Histopathological evaluation of the chemotherapy effect turned out to be a major prognostic factor. Rareness in common practice was one of the reasons for the relative stillness around bone tumours and the vast variety of entities limiting the study of significant numbers of cases to specialized bone tumour centres. Moreover the often heavily calcified nature and sometimes the low cellularity make these tumours difficult to access by molecular techniques. The first important contribution in the field of bone tumour pathology has come from the identification of a specific translocation t[11,22] and its variants in Ewing sarcoma, which acted as a paradigm for the genetic research of mesenchymal tumours in the eighties but only in the field of soft tissue tumours[1-3]. Recently, bone tumour pathology field seems to grow alongside with its "soft" counterparts, mainly because of recent advances on genetics. Hereunder we illustrate these developments on the two most prevalent primary malignant bone tumours: conventional osteosarcoma and conventional chondrosarcoma.

Osteosarcoma

Osteosarcoma is a highly malignant osteoid-forming bone tumour.[2-6] As a result of the use of adjuvant chemotherapy, survival in osteosarcoma has increased from 20% in 1960 to 1970 to 55-80% from 1970 to 1985, as a result of the use of adjuvant chemotherapy. Since the last decade, no further substantial improvement in outcome has been achieved, despite the use of advanced multi-modal and intensive therapy. Studies looking into aetiology have not shown any relationship with virus infections, environmental factors or trauma.[3] An increased incidence (2.7-40 times) of osteosarcoma has been described in patients who have received previous radiation therapy and/or chemotherapy, particularly alkylating agents, for other cancers.[4] Every osteosarcoma for which such external aetiological causes are suspected occurs in adults and especially in the elderly. Thereby it suggests that in children and young adults this potentially concerns another disease than osteosarcoma. Some clinical conditions

Correspondence
P. C.W. Hogendoorn
Department of Pathology, Leiden University Medical Centre,
Building 1, L1Q,
PO Box 9600, 2300 RC
Leiden, The Netherlands
fax: 31 71 5248158.
e-mail: p.c.w.hogendoorn@lumc.nl

have been described to be related to osteosarcoma, like Paget's disease, or genetic disorders like Rothmund-Thomson and Li-Fraumeni syndromes, retinoblastoma and multiple osteochondromas (MO; previously known as hereditary multiple exostoses).[3] Interestingly the concurrence of multiple malignancies appears to be reflected by an uncommon phenotype of osteosarcoma.[5]

Histology, pathology and classification

Osteosarcoma can be subdivided, according to the WHO 2002 classification,[6] into conventional, the most frequent, teleangiectatic, small cell, parosteal and periostal types. Further subdivision of the conventional osteosarcoma into osteoblastic, chondroblastic and fibroblastic subtypes has only shown marginal influences on histological response and clinical outcome.[7] Although chondroblastic osteosarcoma responds relatively poorly to chemotherapy,[7] its disease-free survival rate is higher.

Natural history of osteosarcoma

If treated by amputation alone, nearly all patients will develop pulmonary metastases, indicating that most patients have micrometastatic spread at the time of diagnosis.[8-10] Long-term survivors after single surgical treatment account for 5-20%.[2,8,11-12] However, it has been debated that reports of survival rates as high as 20% included other lesions than conventional osteosarcoma, and evidences make it believe that post-surgical survival does not exceed 5-10%.[11-12] Around half of the metastatic spread occurs within the first half year and nearly every metastasis develops within the first 2 years after diagnosis, being lethal to the patient.[8,13]

The effect of treatment

Remarkably, surgery has not proven to affect the natural history of osteosarcoma patients. Regardless of the extent of the primary surgical procedure, even coupled with preoperative radiotherapy, the dismal prognosis of osteosarcoma was not influenced.[8,14-15]

The effect of chemotherapy has been reported to increase the 5-year disease-free survival (DFS) and overall survival (OS) to 42% and 67% respectively, using high dose metotrexate as a single cytostatic drug.[16] Combination of active drugs in osteosarcoma revealed, in small early series, a 5-year DFS and OS of 40%-60% and 70%-80% respectively.[12,18-20] In patients with adjuvant chemotherapy not only the number of clinically detectable metastases decreased but they have also occurred later (median 12 vs. 5 months respectively) when compared to a control group.[15] Approximately only one third of osteosarcomas shows a good histological response to preoperative chemotherapy.[17-18] Another beneficial effect of neoadjuvant chemotherapy is the reduction of surgery morbidity.[3]

Many randomised clinical trials or else have attempted to demonstrate that long-term survival was improved by neoadjuvant chemotherapy. Studies in non-metastatic osteosarcoma of the extremities, treated in a neoadjuvant besetting, report long-term disease-free and overall survival rates of 45%-70% and 55%-75%, respectively.[19-20] For osteosarcomas located in the axial skeleton or metastatic osteosarcomas, long-term survival is still unsatisfactory, being 40% and 16% respectively.[21] Increasing drugs dose, or the combination and number of drugs, has not shown to improve outcome.[21-23]

Prognostic factors

Clinical factors that can predict the osteosarcoma outcome have been extensively investigated. Amongst the factors that have been studied are age, gender, symptoms duration, site and tumour size, disease stage, histology, tumour necrosis following chemotherapy, alkaline phosphatase (AP) and lactate dehydrogenase (LDH) serum levels, tumour cells P-glycoprotein and Her-2/neu expression, and pharmacokinetic variables. The studies have yielded different and sometimes conflicting results. The most important prognostic variable for patients with extremity osteosarcoma is considered to be tumour necrosis following chemotherapy.[20,24] No consensus is available for any prognostic variable that might be used for patient stratification before the onset of therapy.

After multivariate analysis it has become clear that metastatic disease at presentation, axial tumours

or tumour located in proximal femur or humerus, response to chemotherapy and surgical remission were the only relevant and independent prognostic factors.[6]

Genetic factors and molecular studies in osteosarcomas

Because of conflicting results from clinical studies, and lack of prognostic variables at diagnosis, the question raised is how genetic factors can be used as predictors of prognosis in osteosarcomas. Osteosarcomas karyotype analysis reveals extremely complex clonal and non-clonal, numerical and structural chromosome aberrations.[25-28] Osteosarcoma-specific chromosome aberrations have not been identified so far. Retinoblastoma gene protein (pRb), p53 gene product, and several other tumour suppressor genes or oncogenes (c-fos, myc and ras) have been described in osteosarcoma.[29-32]

It has been postulated that loss of heterozygosity (LOH) at the Rb gene locus, suggesting involvement of the Rb tumour suppressor gene, is a poor prognostic marker in osteosarcoma.[33] However, others have shown that approximately half of the osteosarcomas with LOH at the Rb locus do express the Rb protein, suggesting that chromosome 13q LOH does not necessarily correlate with Rb gene inactivation.[34] In other studies, p53 abnormalities do not distinguish localised and metastatic osteosarcomas[35-36] nor correlate with histological response to chemotherapy.[33] There have been a few reports about oncogene alterations, (e.g. c-fos, myc), observed only in small series.[30,37]

To summarize, results of biologic studies confirm, as previously shown by morphological analysis, the heterogeneous nature of osteosarcomas. Cytogenetic analysis of osteosarcomas reveals very complex numerical and structural chromosomes aberrations, which are not specific for osteosarcomas, but rather reflect vast genomic instability. Increasing knowledge about cell cycle and spindle-formation regulating genes can correlate cytogenetic with molecular data.

Expression profiling in osteosarcoma

It is the current view that cancer development and progression is influenced by hereditary genetic factors, as well as somatic genetic changes. Many studies on somatic genetic alterations in osteosarcoma have, so far, not led to identification of genes involved in clinical outcome or response to therapy. Genetic instability of these tumours obscures specific genetic events. Therefore, other approaches are necessary to investigate the RNA and protein expression profile. Tumours cDNA microarray analyses have gained their merits on tumour classification,[38] new subtypes identification on basis of gene expression[39] and clinical outcome prediction.[40] One report describes a cDNA microarray study on three osteosarcoma cell lines,[41] however it is not clear how its data can be translated to conclusions on clinical outcome of primary osteosarcoma. Khanna[42] has shown, in a murine model, that in metastatic osteosarcoma 53 genes were differentially expressed compared with less aggressive models. Some of these genes were previously unknown, and played a role in adhesion, enhanced motility, invasion, changes in cytoskeleton and angiogenesis. Further identification of these metastasis-related genes, like Ezrin, has to be done. These findings have confirmed the complexity of

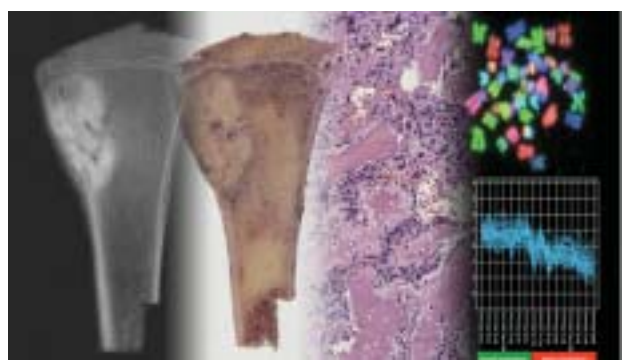

Figure 1 - From Macroscopy to molecules: Osteosarcoma. Osteosarcoma is the most common malignant primary tumour of bone. It occurs mostly in young patients affecting epi-methaphyseal region of long bones. Radiology shows a sclerotic lesion destructing the cortex of a skeletally immature tibia, the growth plate is still open. Histology shows pleomorphic neoplastic cells permeating the bone marrow. Ostoesarcoma is characterized by a complex karyotype most likely due to chromosomal instability (COBRA-FISH). Wide scan expression analysis leads to the identification of both crucial molecules regulating the response to chemotherapy as well as new target for alternative therapy

expression patterns causing phenotypic and biological differences.

Recently, a specific expression signature for chemotherapy-resistant pediatric osteosarcoma has been reported.[43] In particular, osteoclastogenesis and bone resorption-related genes seem highly expressed in poor responders.[43]

Cartilaginous Tumours

Primary malignant bone tumours prevalence is estimated 1:100,000 within general population, 17-24% of which are malignant cartilaginous tumours (chondrosarcomas).[44] Chondrosarcoma is the second most frequent primary malignant bone tumour after osteosarcoma. The preoperative assessment of cartilaginous lesions is based upon careful radiological documentation, clinical presentation and biopsy specimen histopathological evaluation.[45] In general practice, the primary differential diagnosis will be made based upon radiology and clinical-demographic data.[44]

Radiological evaluation

Plain radiographs, in the expert radiologists' hands, so far provide substantial information. In the diagnosis field of cartilaginous tumours, additional progress has been made using (dynamic) MRI, especially for the distinction between benign and low-grade malignant cartilaginous lesions. Regarding the differential diagnosis of osteochondroma versus low-grade peripheral chondrosarcoma, the thickness and staining characteristics on (dynamic) MR of the cartilaginous cap provide a rather reliable assessment of the likelihood of malignancy.[46] For the distinction between enchondroma and central grade I chondrosarcoma, clinical symptoms and radiographic features are helpful, but both lack specificity.[47-48] Localisation in the axial skeleton and size greater than 5 cm have been shown to be reliable predictors for malignancy.[49] Previous studies have demonstrated that conventional radiography is not reliable in this differential diagnosis, as it is, amongst others, hampered by the absence of objective and reproducibility criteria[49]. Although recent studies using dynamic contrast enhanced MR-imaging have shown increased sensitivity[46,50], even by evaluation of an experienced bone tumour radiologist, an absolute distinction between malignant and benign can not be made on radiological grounds by itself.[49,51-52] Therefore, when the radiological assessment of a benign versus a low-grade malignant central cartilaginous tumour remains doubtful, a biopsy has to be taken and assessed by a skilled pathologist, who evaluates the biopsy using all radiological information available applying defined histopathological criteria.

Osteochondroma

Osteochondroma (osteocartilaginous exostosis) is defined as a bony projection covered by a cartilaginous cap on bone external surface.[53] The stalk consists of medullar and cortical bone and projects from bone surface. They may have either a broad base (sessile) or a narrow base (pedunculated). The medulla within the lesion is in direct connection with the long bone marrow from which it originates. The lesion is completely covered by periosteum. Stratified zones of chondrocytes that are normally found in the growth plate can sometimes be recognised in osteochondroma. At radiography, osteochondroma is characterised by its typical location at the transition from metaphysis to diaphysis, its projection away from the joint, the cortex continuity from the bone with the osteochondroma stalk cortex, and the presence of central spongiosa of the stalk. Osteochondromas are frequent lesions, which develop and increase in size in the first decade of life, ceasing their development when the growth plates close at puberty. The majority is asymptomatic. The osteochondroma solitary (sporadic) form is approximately 6 times more frequent than the occurrence within the context of multiple osteochondromas (MO).[44,54] MO (previously known as hereditary multiple exostosis, EXT or diaphyseal aclasis) is an autosomal dominant condition characterised by the presence of multiple osteochondromas resulting in a variety of orthopaedic deformities.[55-58] Males are more often affected possibly due in part to an incomplete penetrance in females.[55] MO is genetically heterogeneous and two genes, *EXT1* and *EXT2* located respectively on 8q24

and 11p11-p12 have been isolated.[59-62] Malignant transformation is low in single osteochondromas (<1% of cases) but it is estimated to occur in 1-5% of hereditary multiple exostoses cases.[57,63]

Osteochondroma was initially regarded as a perversion in the direction of normal bone growth resulting from aberrant epiphyseal development with displacement of epiphyseal cartilage, instead of a true neoplasm.[64-65] However, recent studies have pointed towards a neoplastic origin: cytogenetic abnormalities, aneuploidy and loss of heterozygosity have been clearly shown in osteochondroma cartilaginous cap.[66,67-79]

Chondrosarcoma

Chondrosarcoma of bone is a malignant bone tumour characterised by cartilage formation, instead of bone, by tumour cells.[68] Well-differentiated extraskeletal chondrosarcomas are rare and if such a tumour is found in soft tissues it is more likely an extension or a bone tumour metastasis. Chondrosarcoma of bone is distinguished from (en)chondroma by its higher cellularity, nuclear pleomorphism, its plump cells with large or double nuclei, while mitoses are infrequent. However, the distinction between benign and low-grade tumours is considered difficult both at the radiological[49] and histological[69] level. Consequently, the diagnosis is usually based on a combination of clinical, radiological and histological findings. At histological level, the distinction between enchondroma and low grade central chondrosarcoma is mainly based on a variety of growth patterns, in which, amongst others, the presence of entrapment and the absence of encasement favour malignancy.[48,69-70] A higher expression of JunB in grade I Chondrosarcoma versus enchondroma has been reported, which appears to be promising in terms of diagnostic relevance.[71]

Chondrosarcoma occurs mainly in adults, in the third to sixth decade of life with equal gender incidence rate. They usually develop in thoracic, pelvic and long bones. Surgical treatment is the mainstay of therapy, since these tumours are highly resistant to chemotherapy and radiotherapy. Conventional chondrosarcomas can be categorised according to their location in bone. The majority of conventional chondrosarcomas (approximately 75%) are located centrally within the medullar cavity (central chondrosarcoma) and are more often well-differentiated.[44] A minority (about 15%) develops from the bone surface (peripheral chondrosarcoma) as a result of malignant transformation within the cartilage cap of a pre-existing osteochondroma.[44,72] Although it has been previously demonstrated that central and peripheral chondrosarcomas arise from different genetic mechanisms,[73] there are no apparent cytonuclear differences between these two groups. Both central and peripheral chondrosarcomas are histologically classified into three grades using Evans criteria.[74] Ten-year survival rates in central chondrosarcomas of grades I, II and III are 90%, 81% and 43%, respectively, while the corresponding 10-year survival rates in the peripheral (secondary) subtype are, respectively, 83%, 64% and 29%.[74] None of grade I chondrosarcomas metastasized, while metastasis was observed in 10% of grade II and 71% of grade III tumours.[74-75] Up to 13% of recurrent chondrosarcomas exhibited a higher grade of malignancy than the original neoplasm.[74-75]

Since chondrosarcomas are heterogeneous regarding the grade, multiple sections should be examined. Grading is performed in those areas with the highest grade. However, an absolute correlation between histology and biological behaviour is lacking, particularly for chondrosarcomas arising in phalangeal bones, which may have ominous histological features while demonstrating a relatively indolent clinical course.[76-77]

Genetic factors and molecular studies in chondrosarcoma

Chondrosarcoma tumour progression mechanisms are so far poorly understood.

However, down-regulation of matrix-associated and oxidative phosphorylation-related genes simultaneously with glycolysis-related genes increase were shown upon central chondrosarcoma progression[71] using cDNA microarray.

Cytogenetic data available have shown heterogeneous results with a wide variety of

karyotypic complexities ranging from tumours with a single numerical or structural chromosomal aberration to heavily rearranged karyotypes. In most cytogenetic reports no strict difference between primary, secondary, central, or peripheral conventional chondrosarcomas is made resulting in the description of many non–specific structural or numerical aberrations.[77] Although no recurrent structural aberrations are described in these studies, the pattern of changes tends to be non-random. Karyotypic changes found are predominantly total or partial gains and losses. Genomic imbalances more frequently found are: -1p36, -1p13-p22, -4, -5q13-q31, -6q22-qter, +7p13-pter, -9p22-pter, -10p, -10q24-qter, -11p13-pter, -11q25, +12q15-qter, -13q21-qter, -14q24-qter, -18p, -18q22-qter, +19, +20pter-q11, +21q and –22q13. The -13 q was found to be an independent prognostic factor predicting metastasis regardless of tumour grade or size.[78-79]

Recent studies have indicated a marked difference in genetic make up between central and peripheral (secondary to an osteochondroma) chondrosarcomas reflected by a clear difference in the loss of heterozygosity (LOH) pattern, LOH incidence, DNA ploidy status and cytogenetic aberrations[80-81] Focussing on those studies which have reported on the aforementioned chondrosarcomas subgroups specifically reveals the following results: central chondrosarcomas are genetically characterised by near-diploidy with limited LOH, frequently targeted at the 9p12-22 region, which is not seen in peripheral chondrosarcomas, so far.[81] Comparative Genomic Hybridization (CGH) studies have pointed to deletions of chromosome 9p as well.[82] CDKN2A/p16 is a potential targeted gene in this region; however, mutations are not documented in chondrosarcomas yet. The p16 gene promotor region was shown to be hyper-methylated in a substantial number of cases.[83] Central chondrosarcomas and enchondromas have been found to occur in high association with the development of breast cancer at early age, not associated with known breast cancer syndromes such as BRCA1, BRCA2, Li-Fraumeni's syndrome, etc.[84,85] The occurrence of the association of these two tumours has not led to the identification of a responsible gene.

Peripheral chondrosarcomas are genetically characterised by genetic instability, high percentage of LOH and a broad range of DNA ploidy,[73,86] including near-haploidy in low grade tumours and polyploidization in high grade tumours. On karyotypic level no specific chromosomal aberrations have been identified. The most frequent alterations reported involve chromosome 5q and loss of chromosomes or chromosomal arms 8q, 10, 13, 15 and 19p.[81]

Summary and Conclusions

We are living an exciting moment in general understanding of cancer, and particularly in bone sarcomas, particularly. Use of microarray techniques and proteomics approaches promise recognition of gene expression patterns, which could allow prognostically different groups to be identified. In addition, specific target genes that might play a crucial role in tumourigenesis of osteosarcoma and cartilaginous tumours can be identified. Interfering with the expression of such target genes might be the first step in the development of new drugs or a more rational use of already known chemotherapeutic drugs.

The challenge is to integrate the most updated knowledge with consolidated concepts. The power of the recent and sophisticated techniques may turn out to be insignificant if not led by an effective anatomo-clinical study.

References

1. Turc-Carel C, Philip I, Berger M-P, Philip T, Lenoir GM. Chromosomal translocations in Ewing's sarcoma. Letter to the editor. N Engl J Med 1983;309:497-8.
2. Coventry M B, Dahlin DD. Osteogenic sarcoma: a critical analysis of 430 cases. J Bone Joint Surg 1957;39:741-58.
3. Link MP, Gebhardt MC, Meyers PA. Osteosarcoma. In: Pizzo PA, Poplack DG, editors. Principles and practice of pediatric oncology. 2nd ed. Philadelphia: Lippincott Williams & Wilkins; 2002. p.1502-89.
4. Tucker MA, D'Angio GJ, Boice JD Jr., Strong LC, Li FP, Stovall M, et al. Bone sarcomas linked to radiotherapy and chemotherapy in children. N Engl J Med 1987;317:588-93.
5. Hauben EI, Arends J, Vandenbroucke JP, van Asperen CJ, Van Marck E, Hogendoorn PC. Multiple primary malignancies in osteosarcoma patients. Incidence and predictive value of osteosarcoma subtype for cancer syndromes related with osteosarcoma. Eur J Hum Genet 2003;11:611-8.

6. Fletcher CDM, Unni KK, Mertens F. WHO Classification of tumours pathology & genetics. Lyon: IARC Press; 2002. Tumours of bone and soft tissue; p.170-2.
7. Hauben EI, Weeden S, Pringle J, Van Marck EA, Hogendoorn PC. Does the histological subtype of high-grade central osteosarcoma influence the response to treatment with chemotherapy and does it affect overall survival? a study on 570 patients of two consecutive trials of the European Osteosarcoma Intergroup. Eur J Cancer 2002;38:1218-25.
8. Cade S. Osteogenic sarcoma. J Roy Coll Surg Edinburgh 1955;2:79-111.
9. Link MP, Goorin AM, Horowitz M, Meyer WH, Belasco J, Baker A, et al. Adjuvant chemotherapy of high-grade osteosarcoma of the extremity. Updated results of the Multi-Institutional Osteosarcoma Study. Clin Orthop 1991;(270):8-14
10. Marcove RC, Mike V, Hajek JV, Levin AG, Hutter RV. Osteogenic sarcoma under the age of twenty-one: a review of one hundred and forty-five operative cases. J Bone Joint Surg Am 1970;52:411-23.
11. Lindblom A, Soderberg G, Spjut H. Osteosarcoma: a review of 96 cases. Acta Radiol 1961;56:1-19.
12. Jaffe H L. Tumours and tumours conditions of the bones and joints. Philadelphia; Lea & Febrige; 1958: Osteogenic sarcoma; p.256-78.
13. Jeffree GM, Price CH, Sissons HA. The metastatic patterns of osteosarcoma. Br J Cancer 1975;32:87-107.
14. Huvos AG, Rosen G, Marcove RC. Primary osteogenic sarcoma: pathologic aspects in 20 patients after treatment with chemotherapy en bloc resection, and prosthetic bone replacement. Arch Pathol Lab Med 1977;101:14-8.
15. Pratt CB, Champion JE, Fleming ID, Rao B, Kumar AP, Evans WE, et al: Adjuvant chemotherapy for osteosarcoma of the extremity: long-term results of two consecutive prospective protocol studies. Cancer 1990; 65:439-45.
16. Goorin AM, Abelson HT, Frei E. Osteosarcoma: fifteen years later. N Engl J Med 1985; 313:1637-43.
17. Bramwell VHC, Burgers M, Sneath R, Souhami R, Van Oosterom AT, Voûte PA, et al. A comparison of two short intensive adjuvant chemotherapy regimens in operable osteosarcoma of limbs in children and young adults: The first study of the European Osteosarcoma Intergroup. J Clin Oncol 1992; 10:1579-91.
18. Solheim OP, Saeter G, Elomaa I, Alvegard TA. The treatment of osteosarcoma: present trends: The Scandinavian Sarcoma Group experience. Ann Oncol 1992; 3 (Suppl 2):S7-S11.
19. Meyers PA, Heller G, Healey J, Huvos AG, Lane J, Marcove RC, et al. Chemotheray for nonmetastatic osteogenic sarcoma: the Memorial Sloan-Kettering experience. J Clin Oncol 1992;10:5-15.
20. Bielack SS, Kempf-Bielack B, Delling G, Exner GU, Flege S, Helmke K, et al. prognostic factors in high-grade osteosarcoma of the Extremities or Trunk: an analysis of 1,702 patients treated on neoadjuvant Cooperative Osteosarcoma Study Group Protocols. J Clin Oncol 2002;20:776-90.
21. Voute PA, Souhami RL, Nooy M, Somers R, Cortes-Funes H, van-der Eyken JW, et al. A phase II study of cisplatin, ifosfamide and doxorubicin in operable primary, axial skeletal and metastatic osteosarcoma. Ann Oncol 1999;10:1211-8.
22. Bramwell VH, Burgers M, Sneath R, Souhami R, Van Oosterom AT, Voute PA, et al. A comparison of two short intensive adjuvant chemotherapy regimens in operable osteosarcoma of limbs in children and young adults: the first study of the European Osteosarcoma Intergroup. J Clin Oncol 1992;10:1579-91.
23. Fuchs N, Bielack SS, Epler D, Bieling P, Delling G, Korholz D, et al. Long-term results of the co-operative German-Austrian-Swiss osteosarcoma study group's protocol COSS-86 of intensive multidrug chemotherapy and surgery for osteosarcoma of the limbs. Ann Oncol 1998; :893-9.
24. Davis AM, Bell RS, Goodwin PJ. Prognostic factors in osteosarcoma: a critical review. J Clin Oncol 1994;12:423-31.
25. Mandahl N, Heim S, Kristoffersson U, Mitelman F, Rydholm A, Rooser B, et al. Multiple cytogenetic abnormalities in a case of osteosarcoma. Cancer Genet Cytogenet 1986;23:257-60.
26. Mertens F, Mandahl N, Orndal C, Baldetorp B, Bauer HCF, Rydholm A, et al. Cytogenetic findings in 33 osteosarcomas. Int J Cancer 1993;55:44-50.
27. Fletcher JA, Gebhardt MC, Kozakewich HP. Cytogenetic aberrations in osteosarcomas. Nonrandom deletions, rings, and double-minute chromosomes. Cancer Genet Cytogenet 1994;77:81-8.
28. Bridge JA, Nelson M, McComb E, McGuire MH, Rosenthal H, Vergara G, et al. Cytogenetic findings in 73 osteosarcoma specimens and a review of the literature. Cancer Genet Cytogenet 1997;95:74-87.
29. Wu JX, Carpenter PM, Gresens C, Keh R, Niman H, Morris JW, et al. The proto-oncogene c-fos is over-expressed in the majority of human osteosarcomas. Oncogene 1990;5:989-1000.
30. Pompetti F, Rizzo P, Simon RM, Freidlin B, Mew DJ, Pass HI, et al. Levine AS, and Carbone M: Oncogene alterations in primary, recurrent, and metastatic human bone tumours. J Cell Biochem 1996;63:37-50.
31. Patino-Garcia A, Sierrasesumaga L. Analysis of the p16INK4 and TP53 tumour suppressor genes in bone sarcoma pediatric patients. Cancer Genet Cytogenet 1997;98:50-5.
32. Tsuchiya T, Sekine K, Hinohara S, Namiki T, Nobori T, Kaneko Y. Analysis of the p16INK4, p14ARF, p15, TP53, and MDM2 genes and their prognostic implications in osteosarcoma and Ewing sarcoma. Cancer Genet Cytogenet 2000;120:91-8.
33. Feugeas O, Guriec N, Babin-Boilletot A, Marcellin L, Simon P, Babin S, et al. Loss of heterozygosity of the RB gene is a poor prognostic factor in patients with osteosarcoma. J Clin Oncol 1996;14:467-72.
34. Wadayama B, Toguchida J, Shimizu T, Ishizaki K, Sasaki MS, Kotoura Y, et al. Mutation spectrum of the retinoblastoma gene in osteosarcomas. Cancer Res 1994;54:3402-48.
35. Lonardo F, Ueda T, Huvos AG, Healey J, Ladanyi M. p53 and MDM2 alterations in osteosarcoma; correlation with clinicopathologic features and proliferative rate. Cancer 1997;79:1541-7.
36. Gokgoz N, Wunder JS, Mousses S, Eskandarian S, Bell RS, Andrulis IL. Comparison of p53 mutations in patients with localized osteosarcoma and metastatic osteosarcoma. Cancer 2001;92:2181-9.
37. Kakar S, Mihalov M, Chachlani NA, Ghosh L, Johnstone H. Correlation of c-fos, p53, and PCNA expression with treatment outcome in osteosarcoma. J Surg Oncol 2000;73:125-6.
38. Golub TR, Slonim DK, Tamayo P, Huard C, Gaasenbeek M, Mesirov JP, et al. Molecular classification of cancer: class discovery and class prediction by gene expression monitoring. Science 1999;286:531-7.
39. Perou CM, Sorlie T, Eisen MB, van de RM, Jeffrey SS, Rees CA, et al. Molecular portraits of human breast tumours. Nature 2000;406:747-52.
40. Van 't Veer LJ, Dai H, Van de Vijver MJ, He YD, Hart AA, Mao M, et al. Gene expression profiling predicts clinical outcome of breast cancer. Nature 2002;415:530-6.
41. Wolf M, El Rifai W, Tarkkanen M, Kononen J, Serra M, Eriksen EF, et al. Novel findings in gene expression detected in human osteosarcoma by cDNA microarray. Cancer Genet Cytogenet 2000;123:128-32.
42. Khanna C, Khan J, Nguyen P, Prehn J, Caylor J, Yeung C, et al. Metastasis-associated differences in gene expression in a murine model of osteosarcoma. Cancer Res 2001;61:3750-9.
43. Mintz MB, Sowers R, Brown KM, Hilmer SC, Mazza B, Huvos AG, et al. An expression signature classifies chemotherapy-resistant pediatric osteosarcoma. Cancer Res 2005;65:1748-54.
44. Mulder JD, Schütte HE, Kroon HM, Taconis WK. Radiologic atlas of bone tumours. Amsterdam: Elsevier; 1993.
45. Bovée JVMG, Cleton-Jansen AM, Taminiau AHM, Hogendoorn PCW. Emerging pathways in the development of chondrosarcoma of bone and the implications for targeted treatment. Lancet Oncol 2005;6:599-607.
46. Geirnaerdt MJA, Bloem JL, Eulderink F, Hogendoorn PCW, Taminiau AHM. Cartilaginous tumours: correlation of gadolineum-enhanced MR Imaging and histopathologic findings. Radiology

1993;186:813-7.
47. Sanerkin NG. The diagnosis and grading of chondrosarcoma of bone: a combined cytologic and histologic approach. Cancer 1980;45:582-94.
48. Schiller AL. Diagnosis of borderline cartilage lesions of bone. Semin Diagn Pathol 1985;2:42-62.
49. Geirnaerdt MJA, Hermans J, Bloem JL, Kroon HM, Pope TL, Taminiau AHM, et al. Usefullness of radiography in differentiating enchondroma from central grade I chondrosarcoma. AJR 1997;169:1097-104.
50. Geirnaerdt MJ, Hogendoorn PCW, Bloem JL, Taminiau AHM, Van der Woude HJ. Cartilaginous tumours: fast contrast-enhanced MR imaging. Radiology 2000;214:539-46.
51. Hudson TM, Manaster BJ, Springfield DS, Spanier SS, Enneking WF, Hawkins Jr IF. Radiology of medullary chondrosarcoma: preoperative treatment planning. Skeletal Radiol 1983;10:69-78.
52. Dietlein M, Féaux de Lacroix W, Neufang KFR, Steinbrich W, Schmidt J. Zur Problematik der Dignitätsbeurteilung von Knorpeltumouren langer Rohrenknochen aus radiologischer und pathologischer Sicht. Rontgen Blatt 1990;174:A180.
53. Khurana J, Abdul-Karim F, Bovée JVMG. Osteochondroma. World Health Organization classification of tumours. In: Fletcher CDM, Unni KK, Mertens F. editors. Pathology and genetics of tumours of soft tissue and bone. Lyon: IARC Press; 2002. p.234-6.
54. Bovée JVMG, Hogendoorn PCW. Multiple osteochondromas. World Health Organization classification of tumours. In: Fletcher CDM, Unni KK, Mertens F. editors. Pathology and genetics of tumours of soft tissue and bone. Lyon: IARC Press; 2002. p.360-2.
55. Legeai-Mallet L, Munnich A, Maroteaux P, Le Merrer M: Incomplete penetrance and expressivity skewing in hereditary multiple exostoses. Clin Genet 1997;52:12-6.
56. Crandall BF, Field LL, Sparkes RS, Spence MA. Hereditary multiple exostoses; report of a family. Clin Orthop 1983;(190)217-9.
57. Wicklund LC, Pauli RM, Johnston D, Hecht JT. Natural history study of hereditary multiple exostoses. Am J Med Genet 1995;55:43-6.
58. Porter DE, Emerton ME, Villanueva-Lopez F, Simpson AHRW. Clinical and radiographic analysis of osteochondromas and growth disturbance in hereditary multiple exostoses. J Pediatr Orthop 2000;20:246-50.
59. Cook A, Raskind W, Blanton SH, Pauli RM, Gregg RG, Francomano CA, et al. Genetic heterogeneity in families with hereditary multiple exostoses. Am J Hum Genet 1993;53:71-9.
60. Ahn J, Ludecke H-J, Lindow S, Horton WA, Lee B, Wagner MJ, et al. Cloning of the putative tumour suppressor gene for hereditary multiple exostoses (EXT1). Nature Genet 1995;11:137-43.
61. Wuyts W, Van Hul W, Wauters J, Nemtsova M, Reyniers E, Van Hul E et al. Positional cloning of a gene involved in hereditary multiple exostoses. Hum Mol Genet 1996;5:1547-57.
62. Stickens D, Clines G, Burbee D, Ramos P, Thomas S, Hogue D et al. The EXT2 multiple exostoses gene defines a family of putative tumour suppressor genes. Nature Genet 1996;14:25-32.
63. Schmale GA, Conrad EU, Raskind WH. The natural history of hereditary multiple exostoses. J Bone Joint Surg [Am] 1994;76A:986-92.
64. Dorfman HD, Czerniak B. Bone tumours. St. Louis: C V Mosby; 1998.
65. Huvos AG. Bone tumours. diagnosis, treatment, and prognosis. Philadelphia: W B Saunders; 1991.
66. Bridge JA, Nelson M, Orndal C, Bhatia P, Neff JR. Clonal karyotypic abnormalities of the hereditary multiple exostoses chromosomal loci 8q24.1 (EXT1) and 11p11-12 (EXT2) in patients with sporadic and hereditary osteochondromas. Cancer 1998;82:1657-63.
67. Mertens F, Rydholm A, Kreicbergs A, Willen H, Jonsson K, Heim S et al. Loss of chromosome band 8q24 in sporadic osteocartilaginous exostoses. Genes Chromosomes Cancer 1994;9:8-12.
68. Bertoni F, Bacchini P, Hogendoorn PCW. Chondrosarcoma. World Health Organisation classification of tumours. In: Fletcher CDM, Unni KK, Mertens F. editors. Pathology and genetics of tumours of soft tissue and bone. Lyon: IARC Press; 2002. p.247-51.
69. Mirra JM, Gold R, Downs J, Eckardt JJ. A new histologic approach to the differentiation of enchondroma and chondrosarcoma of the bones. A clinicopathologic analysis of 51 cases. Clin Orthop 1985;(201):214-37
70. Brien EW, Mirra JM, Kerr R. Benign and malignant cartilage tumours of bone and joint: their anatomic and theoretical basis with an emphasis on radiology, pathology and clinical biology I. The intramedullary cartilage tumours. Skeletal Radiol 1997;26:325-53.
71. Rozeman LB, Hameetman L, van Wezel T, Taminiau AHM, Cleton-Jansen AM, Hogendoorn PCW et al. cDNA expression profiling of central chondrosarcomas: Ollier disease resembles solitary tumours and alteration in genes coding for energy metabolism with increasing grade. J Pathol 2005;207:61-71.
72. Springfield DS, Gebhardt MC, McGuire MH. Chondrosarcoma: a review. J Bone Joint Surg [Am] 1996;78A:141-9.
73. Bovée JVMG, Cleton-Jansen AM, Kuipers-Dijkshoorn N, Van den Broek LJCM, Taminiau AHM, Cornelisse CJ et al. Loss of heterozygosity and DNA ploidy point to a diverging genetic mechanism in the origin of peripheral and central chondrosarcoma. Genes Chromosomes Cancer 1999;26:237-46.
74. Evans HL, Ayala AG, Romsdahl MM. Prognostic factors in chondrosarcoma of bone: a clinicopathologic analysis with emphasis on histologic grading. Cancer 1977;40:818-31.
75. Bjornsson J, McLeod RA, Unni KK, Ilstrup DM, Pritchard DJ. Primary chondrosarcoma of long bones and limb girdles. Cancer 1998;83:2105-19.
76. Bovée JVMG, Van der Heul RO, Taminiau AHM, Hogendoorn PCW. Chondrosarcoma of the Phalanx: a locally aggressive lesion with minimal metastatic potential. A report of 35 cases and a review of the literature. Cancer 1999;86:1724-32.
77. Dorfman HD, Czerniak B. Malignant cartilage tumours. In: Dorfman HD, Czerniak B. editors. Bone tumours. St.Louis: C V Mosby; 1998. p.353-440.
78. Mandahl N, Gustafson P, Mertens F, Akerman M, Baldetorp B, Gisselsson D et al. Cytogenetic aberrations and their prognostic impact in chondrosarcoma. Genes Chromosomes Cancer 2002;33:188-200.
79. Rozeman LB, Hogendoorn PCW, Bovée JVMG. Diagnosis and prognosis of chondrosarcoma of bone. Expert Rev Mol Diagn 2002;2:461-72.
80. Bovée JVMG, Cleton-Jansen AM, Wuyts W, Caethoven G, Taminiau AHM, Bakker E et al. EXT-mutation analysis and loss of heterozygosity in sporadic and hereditary osteochondromas and secondary chondrosarcomas. Am J Hum Genet 1999;65:689-98.
81. Bovée JVMG, Sciot R, Dal Cin P, Debiec-Rychter M, Van Zelderen-Bhola SL, Cornelisse CJ et al. Chromosome 9 alterations and trisomy 22 in central chondrosarcoma: a cytogenetic and DNA flow cytometric analysis of chondrosarcoma subtypes. Diagn Mol Pathol 2001;10:228-36.
82. Larramendy ML, Tarkkanen M, Valle J, Kivioja AH, Ervasti H, Karaharju E, et al. Gains, losses, and amplifications of DNA sequences evaluated by comparative genomic hybridization in chondrosarcomas. Am J Pathol 1997; 150:685-91.
83. Asp J, Brantsing C, Benassi MS, Inerot S, Sangiorgi L, Picci P et al. Changes in p14(ARF) do not play a primary role in human chondrosarcoma tissues. Int J Cancer 2001;93:703-5.
84. Odink AE, van Asperen CJ, Vandenbroucke JP, Cleton-Jansen AM, Hogendoorn PC. An association between cartilaginous tumours and breast cancer in the national pathology registration in The Netherlands points towards a possible genetic trait. J Pathol 2001;193:190-2.
85. Cleton-Jansen AM, Timmerman MC, Van de Vijver MJ, van Asperen CJ, Kroon HM, Eilers PH et al. A distinct phenotype characterizes tumours from a putative genetic trait involving chondrosarcoma and breast cancer occurring in the same patient. Lab Invest 2004;84:191-202.
86. Bovée JVMG, Royen Mv, Bardoel AFJ, Rosenberg C, Cornelisse CJ, Cleton-Jansen AM, et al. Near-haploidy and subsequent polyploidization characterize the progression of peripheral chondrosarcoma. Am J Pathol 2000;157:1587-95.

(Footnotes)

1 "If a man never contradicts himself, the reason must be that he virtually never says anything at all. (quoted from conversation) (Miguel de Unamuno). What is life, the physical aspect of the living cell. Erwin Schrödinger, Cambridge University Press; 1945. p.76."