

Case Report

Collision Tumor at The Esophagogastric Junction: a Case Report

Carlos Eduardo Rodrigues Santos,¹ Antonio Carlos Accetta,² Eduardo Linhares Riello de Mello,³ Ivanir Martins de Oliveira,⁴ Leandro Flores de Freitas Machado,⁵ Jurandir de Almeida Dias,⁶

1 Staff on Surgical Oncology of Nacional Cancer Institute of Brazil. Assistant Professor of Surgery of UNIGRANRIO School of Medicine. Rio de Janeiro, Brazil.

2 Resident on Surgical Oncology of Nacional Cancer Institute, Rio de Janeiro, Brazil.

3 Staff of the Division of Abdomino-Pelvic Surgery, Nacional Cancer Institute, Rio de Janeiro, Brazil

4 Pathologist of Nacional Cancer Institute, Rio de Janeiro, Brazil

5 Medicine Student of UNIGRANRIO School of Medicine, Rio de Janeiro, Brazil

6 Chairman of the Division of Abdomino-Pelvic Surgery, Nacional Cancer Institute, Rio de Janeiro, Brazil

Key words: Esophageal Neoplasms. Stomach Neoplasms. Carcinoma, Squamous Cell. Esophagogastric Junction.

Introduction

Collision tumors represent a coexistence of two adjacent but histologically distinct tumors without histologic admixture in an organ. The occurrence of CT (collision tumor) at the EGJ (esophagogastric junction) is rare, with few cases reported in the literature. Therefore, reports evaluating treatment and survival of this group are scarce.

In this article, we report a collision case between esophageal squamous cell carcinoma and adenocarcinoma at the EGJ, operated in Abdomino-Pelvic Surgery Division of Brazilian National Cancer Institute.

Case Report

A thirty-seven year-old Caucasian man with loss of weight history, retroesternal burning and dysphagia for solid food in the last two months was registered in our hospital in May 2000. He had history of smoking in the last 15 years (30 packets/year) and moderate alcohol consumption. There were no abnormal findings in the physical examination, except for anemia in the conjunctiva.

We did an upper gastrointestinal endoscopy which showed an ulcerated and narrowing lesion with 5cm in length at the lower esophagus, occupying 60 percent

of its circumference and invading the EGJ. A diagnosis of moderately differentiated squamous cell carcinoma (SCC) was made by biopsy. Computed tomography of the chest demonstrated abnormal wall thickening of distal esophagus, while abdominal scan showed no evidence of metastasis.

We did a subtotal transhiatal esophagogastric resection and reconstruction with gastric tube. The patient had a good recovery and was discharged on the 14th postoperative day.

Gross examination of the resected specimen showed ulcerated tumor, measuring 7.5 x 6.0 x 0.6cm occupying the lower esophagus and EGJ (Figure 1). Thirty-seven lymph nodes were isolated, being 20 in right cardial, eight in left cardial, five from mediastinum and four situated on the hepatic pedicle.

Microscopic analysis of the esophageal tumor revealed moderately differentiated SCC invading the adventitia layer. The EGJ tumor was a moderately differentiated adenocarcinoma invading the serosa.

Correspondence

Carlos Eduardo Rodrigues Santos
Praça Cruz Vermelha, 23 – 5o Andar Chefia de Clínica
20230-130 Rio de Janeiro, Brazil
Phone 55 21 25066161
E-mail: carloseduardo@cirurgiaonline.com.br

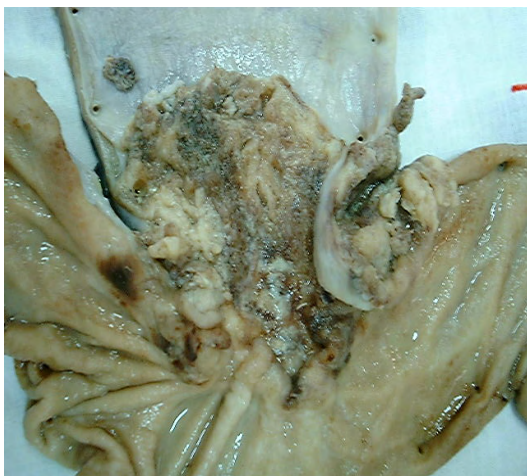

Figure 1 - Gross examination of resected specimen shows ulcerated carcinoma in the lower esophagus and gastric cardia

These two tumors collided at the EGJ, but there was no intermingling (Figure 2). There were neoplastic emboli in lymphatic vessels and perineural invasion, besides metastatic adenocarcinoma in two right cardinal lymph nodes and metastatic SCC in two other right cardinal lymph nodes.

The patient presented disease recurrence with bilateral pleural metastasis seven months after surgery, and died on the 11th postoperative month.

Discussion

CT represents the coexistence in the same organ of two adjacent but histologically distinct tumors without histologic admixture.

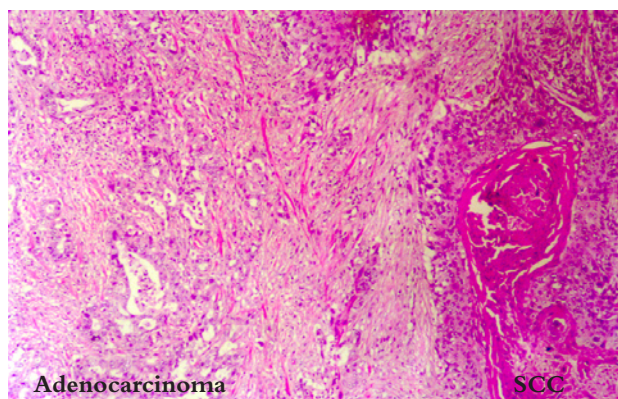


Figure 2 - Microscopic analysis shows collision of squamous cell carcinoma (right side) and adenocarcinoma (left side). H&E x 100

These tumors have been described in various organs of the gastrointestinal tract, including esophagus, stomach, liver, small bowel and rectum, besides other organs as brain, ovary, uterus, lung, thyroid, bone, kidney, adrenal gland, skin and lymph nodes.¹⁻⁴ Most of them were described in case reports.

CT in esophagus and stomach can present many different histological combinations. In the esophagus we have as examples: SCC and leiomyoma,⁵ adenocarcinoma and oat cell carcinoma⁶ or with large cell neuroendocrine carcinoma,⁷ arising these last two CT in a Barrett esophagus. In the stomach, there are reports of adenocarcinoma coexisting with lymphoma,⁸ carcinoid tumor,⁹ Gastrointestinal Stromal Tumor (GIST),¹⁰ and even gastrinoma.¹¹

The mechanism of CTs is uncertain and some hypotheses attempt to elucidate its origin.¹² The simplest explanation is an accidental meeting of two tumors. Other more interesting hypotheses are: a single carcinogenic agent may interact with two neighboring tissues, inducing the development of tumors of different histologic types in the same organ (i.e. association of *Helicobacter pylori* with the synchronous occurrence of mucosa-associated lymphoid tissue lymphoma and adenocarcinoma of the stomach), and another possibility is alteration of the local environment by as first tumor promoting the development of a second tumor (i.e. the development of SCC of the esophagus adjacent to a partially obstructing leiomyoma⁵ or a carcinoid tumor can produce substances which stimulate the growth of a second tumor in the vicinity¹¹).

The occurrence of collision between esophageal SCC and adenocarcinoma at the EGJ is very uncommon, with only 10 reports in the literature.¹⁴⁻²³

In 1919, Meyer²⁴ defined a CT as the accidental meeting and interpenetration of two histologically different tumors from independent primary sites. In 1961, Dodge²⁵ described the first case of a cardia collision carcinoma and proposed three criteria for its diagnosis: 1) the two components should show at least partial topographical separation; 2) the squamous component should be on the esophageal side of the tumor and the adenocarcinoma component on the gastric side; and 3) there should be no evidence of an intermediate histologic structure between the two components in the collision zone. Regarding this last criterion, Wanke¹⁷ and Spagnolo,¹⁹ considered that at the collision zone there would be an intermingling or gradual transition between both components.

In our patient, areas of squamous differentiation

were present in normal esophageal epithelium, while other areas of glandular differentiation were situated in normal gastric epithelium. Both carcinomas were moderately differentiated and collided without intermingling at the EGJ level. Therefore, pathology findings satisfied all Dodge's criteria.

Most CTs at the EGJ are diagnosed on examination of the excised surgical specimens, with the second tumor being discovered as an incidental finding. If a preoperative diagnosis can be done, the patient's prognosis may be improved by the selection of neoadjuvant radiotherapy or chemotherapy¹⁴. In a previous report, CT was treated according to a neoadjuvant chemotherapy trial protocol for SCC, with two courses of cisplatin and etoposide, followed transhiatal esophagectomy. Survival after surgery was only 6 months.¹⁵ However, in the case of our patient, treated only by surgery, global outlife was 11 months. As the reports in literature are very scarce, there is not a consensus about the best treatment to be established in such cases.

CT needs to be distinguished from composite tumors, typically exemplified by adenosquamous carcinoma. Although each of these tumors presents different histological components, CT is originated from different clones, whereas composite tumor results from a common stem cell. In the collision, there is no admixture between the two adjacent tumors, whereas a composite tumor shows a close admixture of two different cell types without an interface defining histological components.

The literature regarding CT consists of a few case reports, most of which are based on histologic appearance and immunohistochemistry. In 2004, Milne²⁶ did a molecular biology study, where the analysis of p53 gene mutation and loss of heterozygosity in two CT showed that tumor components presented identical mutation in this gene, which contradicted the biclonal origin of these components. Therefore, these two cases classified as CT based on histologic appearance did not present compatible molecular findings. Although analyzing few cases, he concluded that it is not possible to recognize a CT only by immunohistologic characteristics. Indeed, if this is true, the occurrence of CT is probably far rarer than referred in the literature.

References

- Goteri G, Ranaldi R, Rezaei B, Baccarini MG, Bearzi I. Synchronous mucosa-associated lymphoid tissue lymphoma and adenocarcinoma of the stomach. *Am J Surg Pathol* 1997;21:505-9.
- Hart AP, Brown R, Lechago J, Truong LD. Collision of transitional cell carcinoma and renal cell carcinoma. *Cancer* 1994;73:154-9.
- Lan KY, Khoo US, Cheung A. Collision of endometriosis carcinoma and stromal sarcoma of the uterus: a report of two cases. *Int J Gynecol Pathol* 1999;18:77-81.
- Chazouilleres O, Andreani T, Boucher JP, Calmus Y, Sigalony H, Nordlinger R et al. Rectal adenocarcinoma in association with lymphoma (collision tumor). *Gastroenterol Clin Biol* 1990;14:185-6.
- Sarbia M, Katoh E, Borchard F. Collision tumor of squamous cell and leiomyoma in the esophagus. *Pathol Res Pract* 1993;189:360-2.
- Gonzalez LM, Sanz-Esponera J, Saez C, Alvarez T, Sierra E, Sanz-Ortega J. Case report: esophageal collision tumor (oat cell carcinoma and adenocarcinoma) in Barrett's esophagus: immunohistochemical, electron microscopy and LOH analysis. *Histol Histopathol* 2003;18:1-5.
- Wilson CI, Summerall J, Willis I, Lubin J, Inchausti BC. Esophageal collision tumor (large cell neuroendocrine carcinoma and papillary carcinoma) arising in a Barrett esophagus. *Arch Pathol Lab Med* 2000;124:411-5.
- Planker M, Fischer JT, Peters U, Borchard F. Synchronous double primary malignant lymphoma of low grade malignancy and early cancer (collision tumor) of the stomach. *Hepatogastroenterol* 1984;31:144-8.
- Morishita Y, Tanaka T, Kato K, Kawamori T, Amano K, Funato T et al. Gastric collision tumor (carcinoid and adenocarcinoma) with gastritis cystica profunda. *Arch Pathol Lab Med* 1991;115:1006-10.
- Liu SW, Chen GH, Hsieh PP. Collision tumor of the stomach: A case report of mixed gastrointestinal stromal tumor and adenocarcinoma. *J Clin Gastroenterol* 2002;35:332-4.
- Leval L, Hardy N, Deprez M, Delwaide J, Belaiche J, Boniver J. Gastric collision between a papillotubular adenocarcinoma and a gastrinoma in a patient with Zollinger-Ellison syndrome. *Virchows Arch* 2002;441:462-5.
- Ng WK, Lan KY, Chan ACL, Kwong TL. Collision tumour of the oesophagus: a challenge for histological diagnosis. *J Clin Pathol* 1996;49:524-6.
- Wotherspoon AC, Isaacson PG. Synchronous adenocarcinoma and low grade B-cell lymphoma of mucosa associated lymphoid tissue (MALT) of the stomach. *Histopathology* 1995;27:325-31.
- Washizawa N, Kobayashi K, Kase H, Tokura N, Gotoh T, Iwasaki I et al. Collision carcinoma at the esophagogastric junction. *Gastric Cancer* 1999;2:240-3.
- Klaase JM, Hulscher JBF, Offerhaus JA, Kate FJW, Obertop H, van Lanschot JJB. Surgery of unusual histopathologic variants of esophageal neoplasms: a report of 23 cases with emphasis on histopathologic characteristics. *Ann Surg Oncol* 2003;10:261-7.
- Huang J, Wistuba I, Gazdar A, Kornaki S, Jagirdar J. Utilization of microdissection, PCR and Loss of Heterozygosity (LOH) in the study of gastroesophageal junction collision tumor: evidence for two separate primaries with different biologic potentials. *Laboratory Investigation* 1997;76:182-5.
- Wanke M. Case report: collision tumor of the cardia. *Virchows Arch Abt A Path Anat* 1972;357:81-6.
- Majmudar B, Dillard R, William SP. Collision carcinoma of the gastric cardia. *Hum Pathol* 1978;9:471-3.
- Spagnolo DV, Heenan PJ. Collision carcinoma at the esophagogastric junction. *Cancer* 1980;46:2702-8.
- Andoh T, Oka Y, Kurokawa S, Hikabe A et al. Collision carcinoma at the cardia diagnosed by endoscopy. Report of a case. I to Cho (Stomach and Intestine) 1991;26:313-9.
- Matsumoto M, Shirao K, Yoshinaka H, Baba M, Fukumoto T, Aikoh T. A case of esophago-residual gastric collision carcinoma. *Rinsho Geka (J Clin Surg)* 1994;49:787-91.
- Maemura T, Sueyoshi S, Shida S, Suga K, Fukushima S, Arakawa M. A case of colliding gastric adenocarcinoma and esophageal squamous cell carcinoma at the esophagogastric junction. *Nippon Rinsho Geka Igakkai Zasshi (J Jpn Soc Clin Surg)* 1997;58:1497-503.
- Kawada S, Murakami S, Noguchi T, Hashimoto T, Uchida Y, Urabe S. A case of collision tumor with esophageal squamous cell carcinoma and gastric signet ring cell carcinoma at the cardia. *Nippon Rinsho Geka Gakkai Zasshi (J Jpn Surg Assoc)* 1998;59:2424-7.

- 24 Meyer R: Beitrag zur verstandigung uber die namengebung in der geschwulstlehre. Zentralbl Pathol 1919;30:291-6.
- 25 Dodge OG: Gastro-esophageal carcinoma of mixed histological type. J Pathol Bacterial 1961;81:459-71.
- 26 Milne NA, Carvalho R, Van Rees BP, Lanschot JJB, Offerhaus JA, Weterman MAJ. Do collision tumors oh the gastroesophageal junction exist? A molecular analysis. Am J Surg Pathol 2004;28:1492-8.